



AMERICAN ASSOCIATION OF ELECTRODIAGNOSTIC TECHNOLOGISTS

PO BOX 2770

CEDAR RAPIDS, IA 52406

877.333.2238

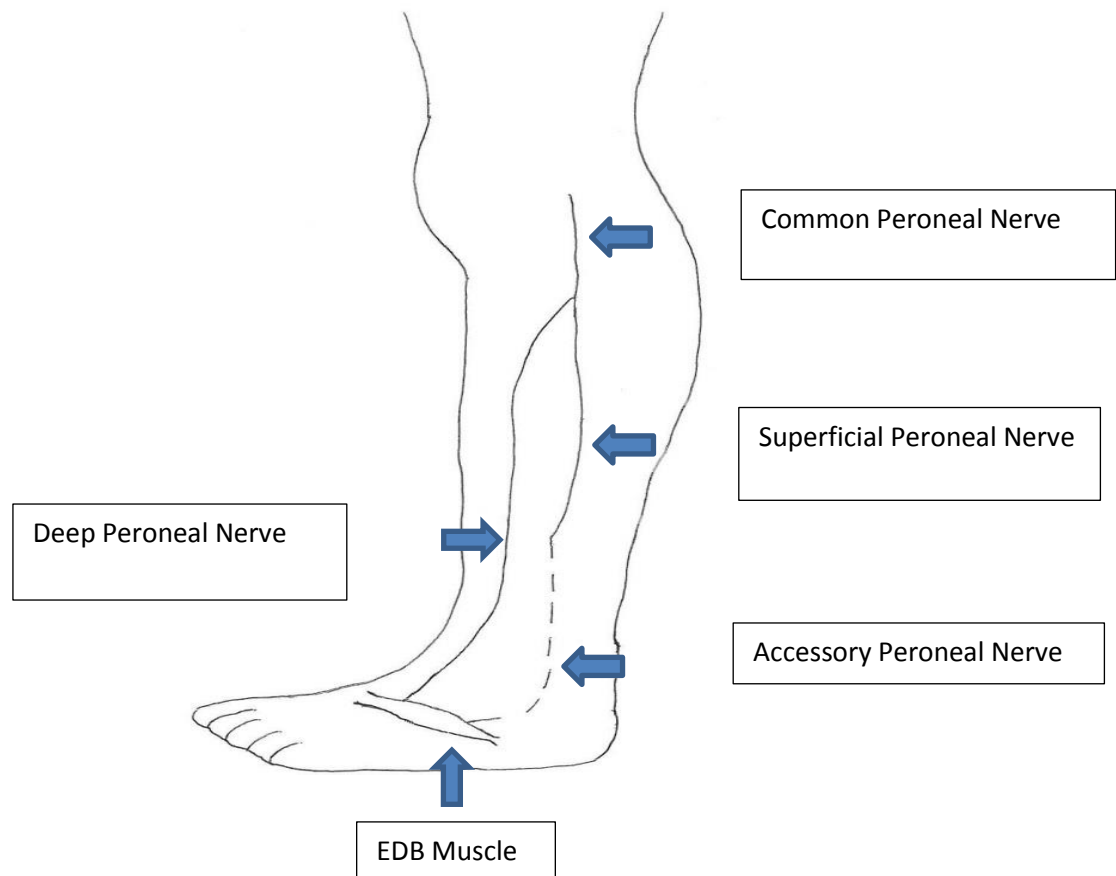
www.aaet.info

The Peroneal Nerve

Peroneal nerve injury can cause decreased sensation, muscle atrophy and loss of movement in the leg or foot. This can occur for a variety of reasons, most commonly in people who already have diseases of the nerve such as neuropathy, those who are very thin, or have had something directly compressing on the nerve. This can occur from crossing the legs, a knee injury, tight casts or placement of the leg during a surgery.

The peroneal nerve derives from L4-S2 nerve root level. The peroneal nerve fibers innervate the short head of the biceps femoris in the thigh, travels down the leg to the lateral cutaneous nerve at the knee before it passes through the fibular tunnel and the peroneus longus muscle and the fibula. At the fibula, the common peroneal nerve divides into the deep and superficial branches. The deep peroneal nerve innervates the tibialis anterior, extensor hallucis longus, peroneus tertius and extensor digitorum brevis and foot dorsiflexors. It also supplies the sensation to the web space between the first and second toes. The superficial peroneal nerve innervates the peroneus longus and peroneus brevis and then as it goes over the dorsum of the foot divides into the medial and intermediate dorsal cutaneous nerves in the foot. The

accessory peroneal nerve, a branch of the superficial nerve, when present as an anomaly runs posterior to the lateral malleolus and supplies the lateral part of the extensor digitorum muscle.



Peroneal neuropathy most often involves both the deep and superficial branches. When the deep branch is affected, patients will have the clinical symptoms of weakness of the toe or foot drop. When the superficial branch is affected there will be weakness in foot eversion. Patients will have trouble bringing their foot up when walking so that it makes a flopping or slapping sound. This can cause them to trip while walking. The patient may complain of pain at the

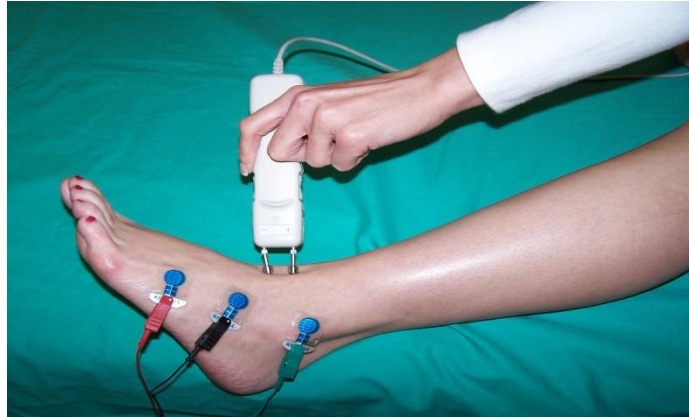
fibular head or a skin sensation change over the mid/lower calf and dorsum of the foot. A peroneal neuropathy usually does not affect reflexes in the leg and foot.

Other disorders may mimic a peroneal neuropathy such as L5 radiculopathy, or a lesion in the sciatic nerve. Nerve conduction studies and EMG proves a useful tool in making a diagnosis.

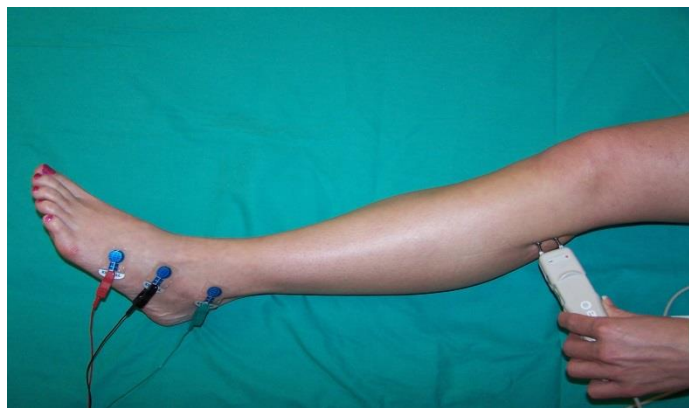When performing motor nerve conduction studies of the peroneal nerve, a recording electrode is placed on the extensor digitorum brevis and a reference electrode at the base of the fifth metatarsal. The ground is placed on the dorsum of the foot. Stimulation is performed at the ankle in between the EHL and EDL tendons, just below the fibular head and the lateral third of the popliteal crease at the knee. Measurements are taken from ankle to below fibula head and below to above fibula head. Accuracy is very important, the longer the distance between the stimulation sites provides a better determination of the conduction velocity. Any drop in amplitude of more than 20 % or focal slowing across the fibular head is a significant finding. Another factor when stimulating is movement of the foot. Make sure the correct nerve is being stimulated by watching for dorsiflexion. If that is not achieved, reposition the cathode and stimulate until proper movement and waveform is seen.

Peroneal Motor Study

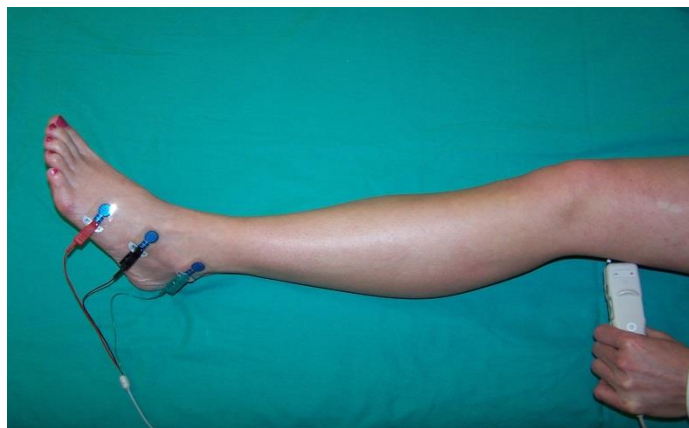
Ankle



Below Fibular Head



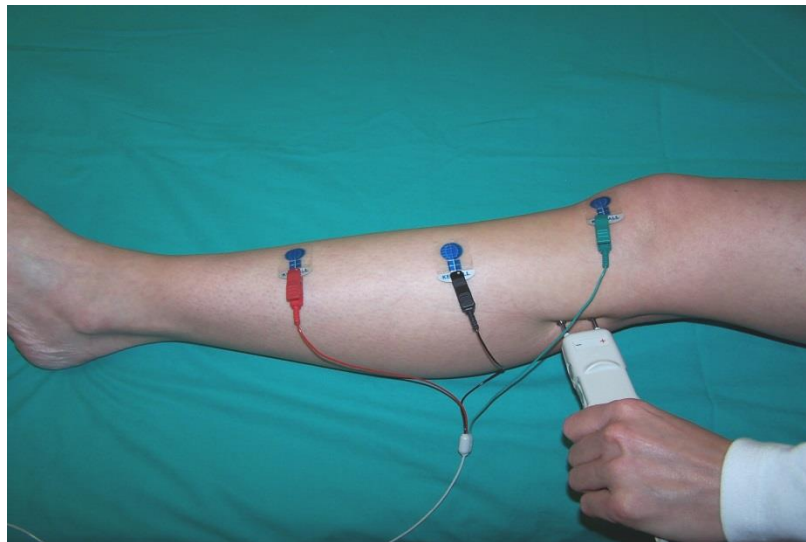
Above Fibular Head



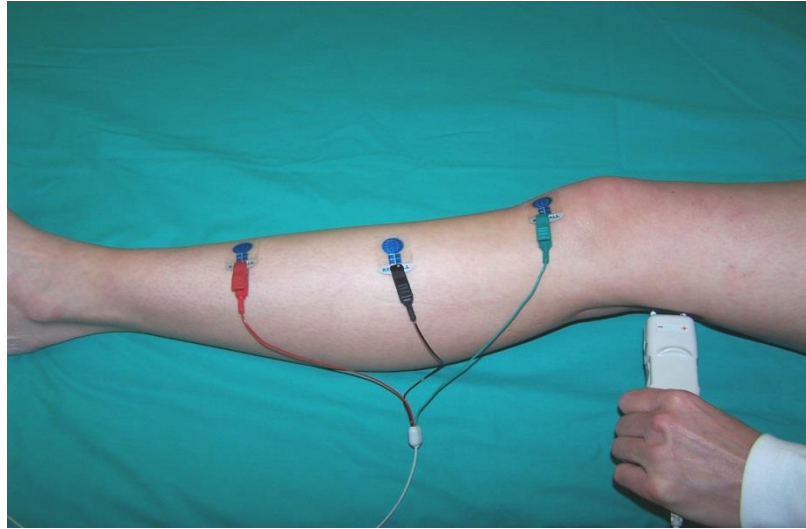
A normal study of the peroneal nerve will have amplitude of at least 2.5mV. If this cannot be obtained, another more proximal peroneal innervated muscle can be recorded from, the tibialis anterior (TA). Place the active electrode on the TA and reference electrode on the medial aspect of the tibia. The ground should be placed between the stimulating and recording electrodes. Stimulation sites are the same used as recording from the EDB muscle. Just below the fibular head and the lateral third of the popliteal crease at the knee. Again, watch the movement of the foot to make sure the correct nerve is being stimulated.

Peroneal -TA Recording

Below fibular Head



Above Fibular Head



When stimulating, on occasion a small amplitude response will be achieved at the ankle and a larger response at the knee. When this occurs, an accessory peroneal should be considered. To prove the anomaly, stimulate posterior to the lateral malleolus and then add the amplitude to the distal amplitude and it will be close to the proximal sites.

The picture below demonstrates an accessory peroneal.

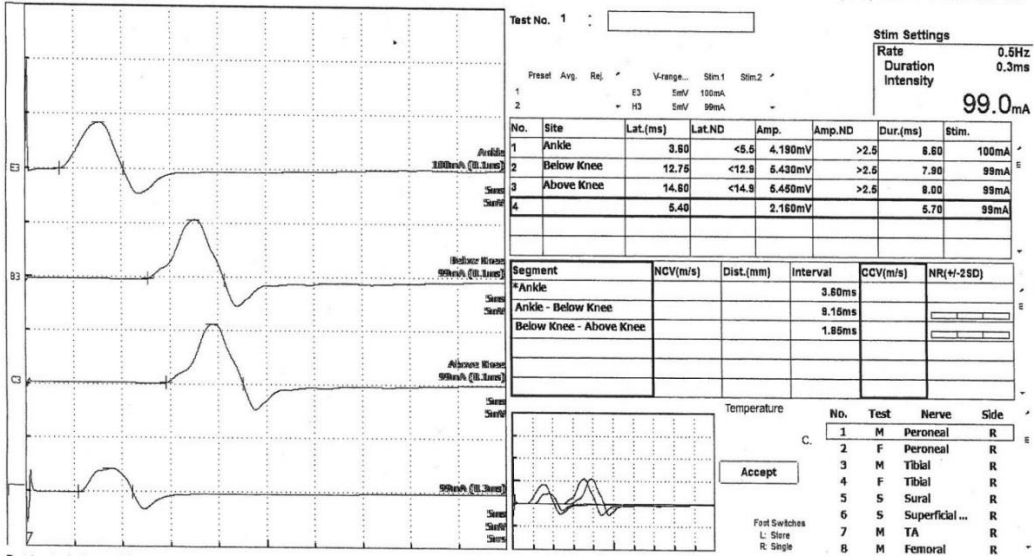
Amplitude

Ankle 4.1

Below Knee 5.4

Above Knee 5.4

Lateral Malleolus 2.2

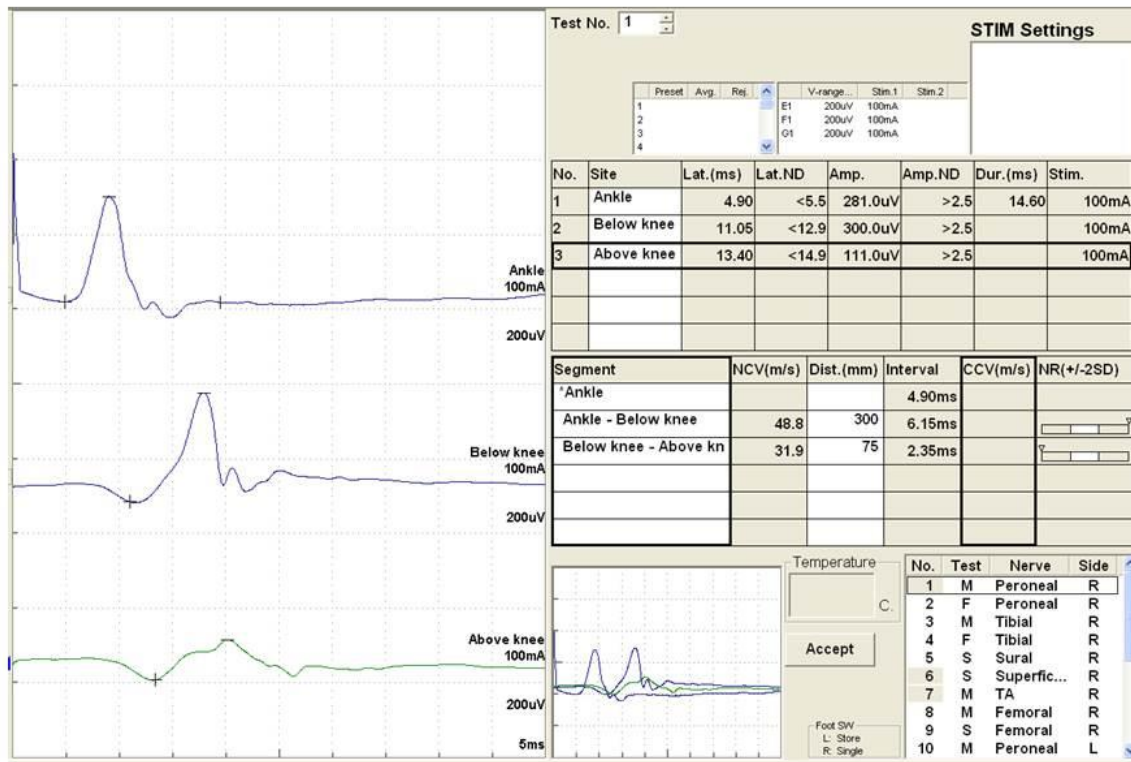


(Ankle) 4.1 + 2.2 (lateral malleolus) =6.3

Amplitude closer to the proximal site of stimulation at 5.4

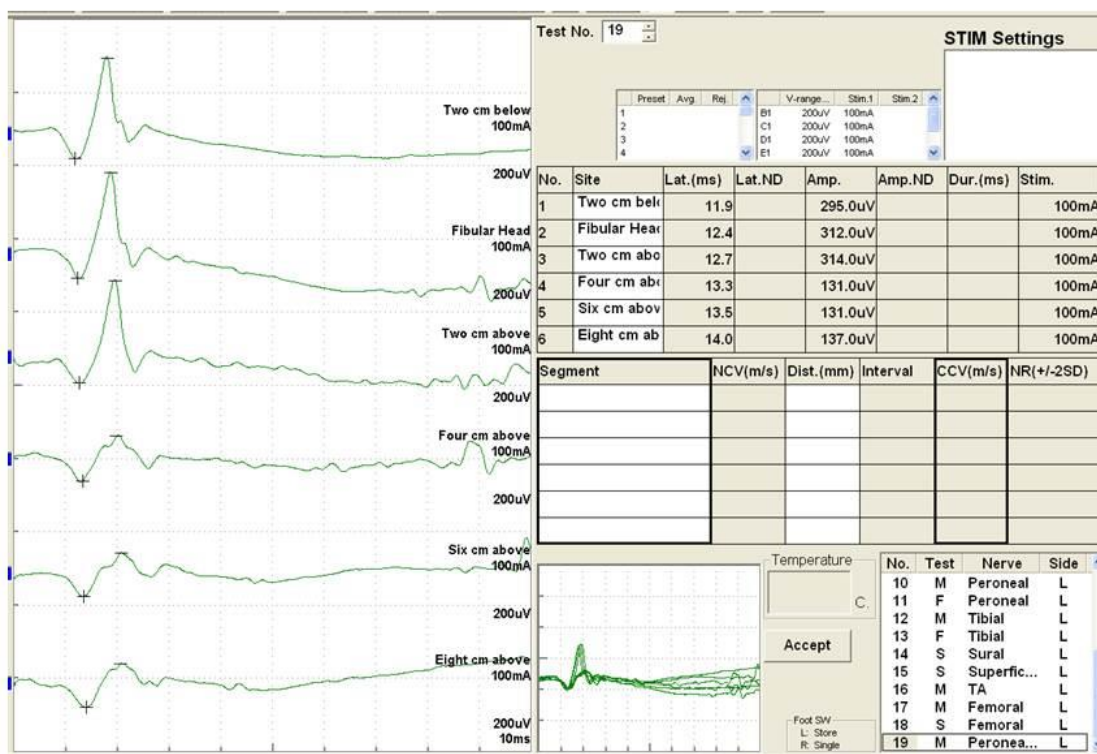
When the amplitude changes in a segment more proximal, a pinched nerve at the fibular head may be possible. If the nerve is damaged, causing a block at the knee the amplitude will drop as in the picture below.

Right Peroneal Motor (EDB)



The inching technique can be used for further localization of entrapment. The study below shows stimulation at two centimeter increments, starting at two centimeters below the fibular head through eight centimeters above the fibular head.

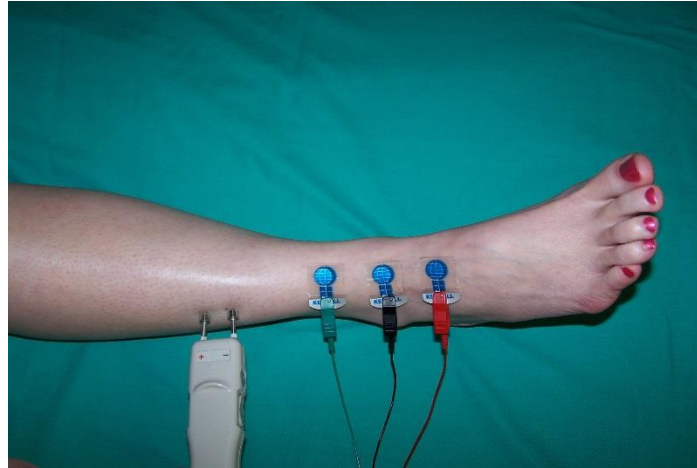
Peroneal Motor Inching (EDB)



Inching is useful to evaluate the shorter segments, it provides a more sensitive measure for localizing focal nerve injury. Since peroneal nerve entrapments most often affect both deep and superficial branches, when performing electrodiagnostic testing both should be evaluated.

To record the superficial peroneal nerve, the active electrode should be placed between the tibialis anterior tendon and lateral malleolus and the reference electrode 3-4 cm distal. The ground is placed between stimulating and recording electrodes. Measure 10 cm from the active recording electrode and stimulate at the lateral calf.

Superficial Peroneal Nerve



After diagnosing a peroneal neuropathy, the next step is treatment and preventing further complications. It takes several months for a nerve to repair and depending on the severity of the damage if it can fully recover. Patients can usually benefit from wearing a brace to support the leg and foot while walking. Physical therapy can help them with muscle strength, and keeping their mobility. Surgery may be necessary to relieve symptoms if caused by a tumor or pressure on the nerve. Corticosteroids are sometimes used to reduced swelling, along with padding the knee to prevent further injury. The patient will be reminded to not cross their legs, as in each time doing so, will further compress the nerve. With electrodiagnostic testing and treatment of the peroneal neuropathy, patients can have good management and prognosis.

Bibliography

Kimura. Electrodiagnosis in Diseases of Nerve and Muscle, Oxford University Press, 2013, p. 128-131

King JC. Peroneal Neuropathy. In: Frontera WR, Silver JK, Rizzo TD, eds. Essential of Physical Medicine and Rehabilitation: Musculoskeletal disorders, pain and rehabilitation, 2nd ed. Philadelphia, PA: Saunders Elsevier; 2008 Ch. 66.

Preston, David and Barbara Shapiro. Electromyography and Neuromuscular Disorders; Clinical Electrophysiologic Correlations. 3rd Ed. Elsevier, Philadelphia. 2013. p.346-356.



AMERICAN ASSOCIATION OF ELECTRODIAGNOSTIC TECHNOLOGISTS

PO BOX 2770

CEDAR RAPIDS, IA 52406

877.333.2238

www.aaet.info