

Carpal Tunnel Syndrome, an overview

Jim Lewis, R.NCS.T.

Learning Objectives:

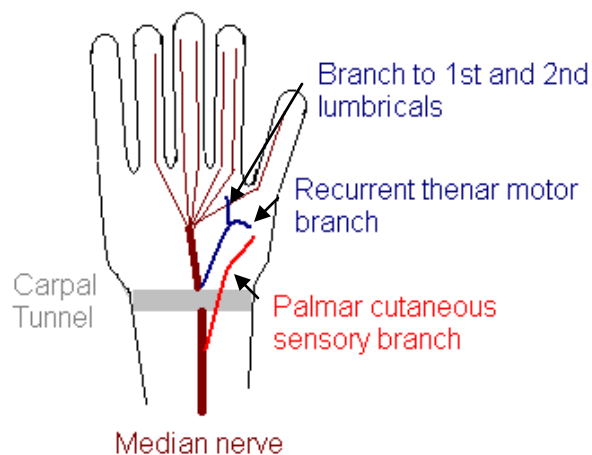
Median nerve compression at the wrist is the most common entrapment seen in the electrodiagnostic laboratory. Although it is not the only entrapment of the median nerve it is, by far, the most common. Carpal Tunnel Syndrome, the term that includes the various collections of symptoms that result from median nerve entrapment at the wrist, is much more common in women than men, by at least a 3:1 ratio.

In this paper will review median nerve anatomy, clinical features of CTS, differential diagnosis, underlying/predisposing conditions, nerve conduction recording parameters, techniques and case studies. The reader will gain insight to this common entrapment as well as the importance of the nerve conduction studies used to confirm the diagnosis of CTS.

Anatomy of the Median Nerve:

Understanding median nerve anatomy is important to sort out the various conditions in that make up the differential diagnosis, whether it is a cervical radiculopathy or a proximal median nerve lesion.

The median nerve, a mixed nerve, arises from cervical roots C6-T1, thus median nerve fibers transverse all three trunks (upper, middle and lower). The nerve continues along via the lateral and medial cords before forming the median nerve proper. There are no median nerve innervations in the upper arm. The nerve continues between or beneath the two heads of the pronator teres muscle in the forearm. The median nerve innervates the pronator teres, flexor digitorum superficialis and flexor carpi radialis before the purely motor nerve branch called the anterior interosseous nerve is given off. The main median nerve branch continues through the forearm and just distal to the wrist it gives off the palmar sensory branch which supplies sensation over the thenar area. Nine flexor tendons and the median nerve go through the tunnel created by the carpal bones on three sides and the transverse carpal ligament on the top. This is called the carpal tunnel. After exiting the carpal tunnel the recurrent thenar motor branch turns around and innervates the muscles of the thenar eminence (abductor pollicis brevis, opponens pollicis and the lateral head of the flexor pollicis brevis). The first and second lumbrical muscles are innervated by the remaining motor



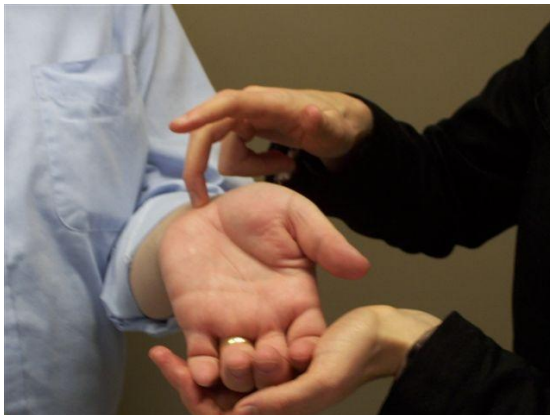Carpal Tunnel Syndrome, an Overview

branch of the median nerve while the sensory branch of the median nerve innervates the medial thumb, forefinger, middle finger and the lateral half of the ring finger.

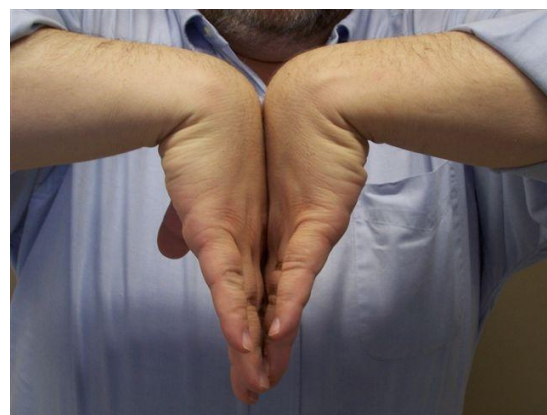Clinical features of CTS:

There may be a variety of signs and symptoms that most commonly includes pain and paresthesias. Women are affected more than men by a wide margin and although CTS can be seen in various ages it is most common in the 5th and 6th decades of life. Carpal tunnel syndrome tends to affect the dominant hand more though bilateral findings are common.

Short lasting pain localized to the wrist and fingers can be the earliest sign, but radiating pain to the forearm, elbow or even shoulder is common. The numbness and burning reported by many patients is maximal in the lateral 3 fingers, but subjectively can include the entire hand. It is important to note that the sensation over the thenar eminence is spared as that area is supplied by the palmar sensory branch given off before the carpal tunnel. Patients often report an increase of pain and paresthesias with movements that flex or extend the wrist such as driving or holding a book. Many patients report the symptoms worsen during the night leading to arousals that require them to shake the feelings back into their hands. This is thought to be secondary to the habit of persistent flexed wrists during sleep. Tinel's sign (tapping the median nerve at the wrist) and Phalen's maneuver (the wrists are held flexed 30 sec. to 1 minute) will generally reproduce the paresthesias. Be careful however, as false positives for both Tinel's and Phalen's are high.



Tinel's sign



Phalen's maneuver

Later in the course, weakness of the thenar muscles can occur. This affects opposition and thumb abduction and when severe can demonstrate thenar atrophy. There may be impairment of activities requiring fine movements, such as buttoning shirts, writing and opening jars.

Differential Diagnosis, Underlying/Predisposing Conditions:

There are several peripheral or even central nervous system lesions that may produce symptoms similar to CTS. Proximal median nerve lesions such as pronator teres syndrome, brachial plexus lesions, cervical radiculopathies and even strokes can mimic CTS. Electrodiagnostic studies are useful sorting these out.

There is a long list of possible predisposing conditions that may lead to the development of CTS. A congenitally small carpal tunnel may explain the female to male ratio difference. Some studies suggest this is a more common factor than repetitive use injuries, which is traditionally thought to be the number one predisposing condition. Wrist or hand trauma, diabetes, pregnancy and connective tissue diseases may also give rise to CTS.

Nerve Conduction Studies:

Nerve conduction studies most often begin with median motor or sensory studies. Ulnar motor and sensory studies are included as a reference to a nerve outside the carpal tunnel. In most cases a comparison study is used to further confirm the localization. F-waves are often performed as part of the routine motor study, but is often less than useful in CTS. Recording a sural sensory study can be useful if bilateral findings, additional ulnar findings or a strong history gives you reason to believe an underlying peripheral neuropathy may be present.

Full technique descriptions follow the introductions.

1. Median sensory study across the wrist at 12-14 cm is considered standard. Many laboratories use antidromic stimulation, while others prefer orthodromic stimulation. While the actual technique is not important it is necessary to be consistent. Use standard sensory amplifier and stimulator settings as noted.
2. Ulnar sensory study across the wrist at 11-13 cm is standard as the ulnar nerve does not pass beneath the transverse carpal ligament. Many laboratories use antidromic stimulation, while others prefer orthodromic stimulation. While the actual technique is not important it is necessary to be consistent. Use standard sensory amplifier and stimulator settings as noted.
3. Comparison sensory/mixed studies are customary, especially if the standard recordings above are equivocal. There are three standard sensory/mixed comparison studies. Use standard sensory amplifier and stimulator settings as noted.
 - a. By far the most common Carpal Tunnel comparison study in the United States is the Transcarpal, median to ulnar mixed nerve comparison, stimulating in the palm and recording over the wrist.
 - b. Less common is the comparison of median and ulnar sensory conduction between wrist and ring finger. Remember the ring finger has sensory innervations from both nerves.

Carpal Tunnel Syndrome, an Overview

- c. Additionally, comparison of median and radial sensory conduction between wrist and thumb is useful when the patient has an ulnar neuropathy and an unaffected nerve that does not go under the transverse carpal ligament is needed.
4. Median motor study to the thenar muscles is a standard. The distal motor latency is important to the evaluation of CTS, but the forearm conduction velocity also verifies the health of the median nerve more proximally. Use standard motor amplifier and stimulator settings as noted.
5. Ulnar motor study to the hypothenar muscle is a standard study as the ulnar nerve does not go under the transverse carpal ligament and would be spared in CTS. Use standard motor amplifier and stimulator settings as noted.
6. F-waves can be performed, however they are not often useful to diagnosis CTS.
7. In cases where no response of the median sensory or motor nerve across the wrist can be obtained the technique for median to 2nd lumbrical to ulnar 2nd volar interosseous can be used. Fascicles to the 2nd lumbrical tend to be spared in even the most severe CTS cases. Use standard motor amplifier and stimulator settings as noted.
8. Needle EMG as performed by the physician is useful to rule out cervical radiculopathy or to gauge severity when the clinical signs indicate.

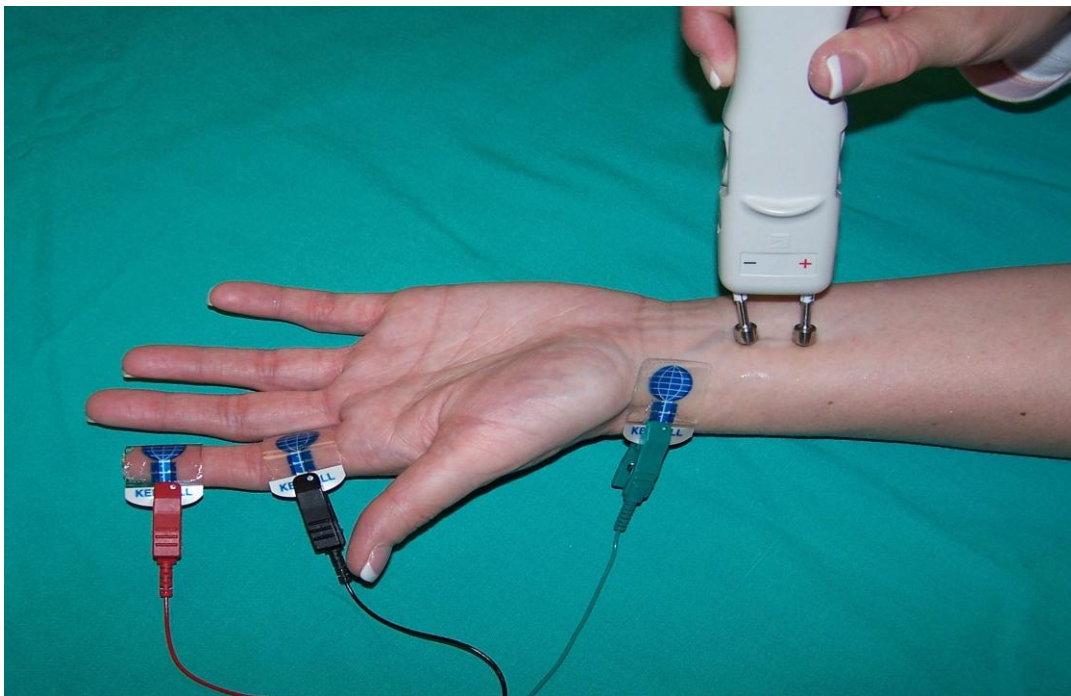
Full technique notes:

Median Sensory Study, Antidromic

Patient Position:	Supine with arm extended at side
Skin Prep:	Clean with alcohol, temperature check (32 – 34 °C per your lab standards)
Recording Parameters:	Sensory NCS Filters: 20Hz – 3kHz, or as your lab standards dictate Timebase/Sweep Speed: 1 or 2 ms/div Gain/Sensitivity: 20 µV/div (starting point)
Recording site:	
Active:	Ring electrode placed on midportion of the proximal phalanx of the index finger (or middle finger)
Reference:	Ring electrode placed on the midportion of the middle phalanx of the index finger (or middle finger)
Ground:	Placed between the stimulating and recording electrodes

Carpal Tunnel Syndrome, an Overview

Stimulation:	(anode is 2.5 cm proximal to cathode)
Wrist:	Applied 12 – 14 cm proximal to the active recording electrode
Stimulation Parameters:	Sensory NCS Stimulus duration: 0.05ms (50 μ sec) or as necessary Intensity: just enough to acquire maximal amplitude
Measurements:	Distance between active recording electrode and stimulation Latency (msec) and amplitude (μ V) for SNAP
Calculations:	Sensory conduction velocity if required



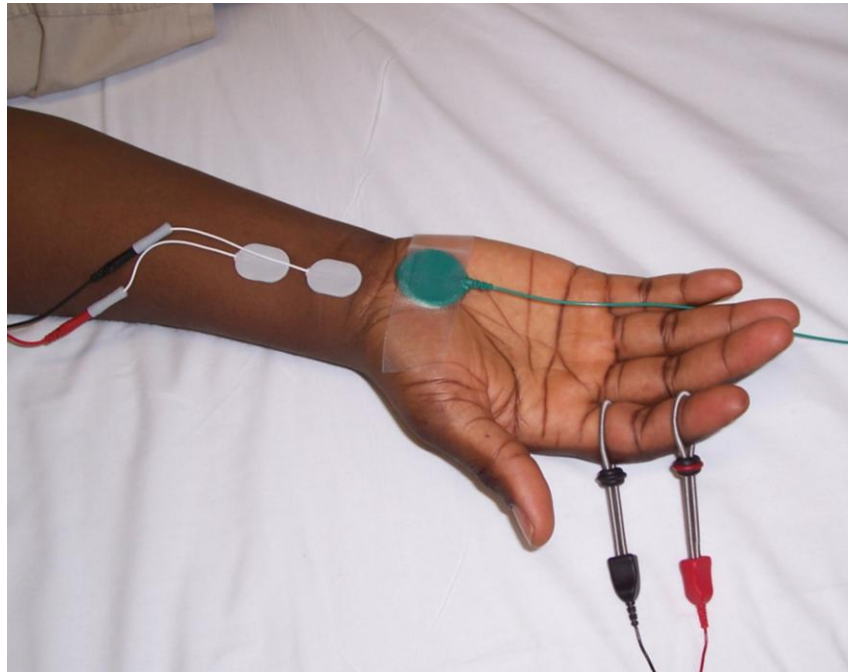
Median Sensory Study, Antidromic

Median Sensory Study, Orthodromic

Patient Position:	Supine with arm extended at side
Skin Prep:	Clean with alcohol, temperature check (32 – 34 °C per your lab standards)

Carpal Tunnel Syndrome, an Overview

Recording Parameters:	Sensory NCS Filters: 20Hz – 3kHz, or as your lab standards dictate Timebase/Sweep Speed: 1 or 2 ms/div Gain/Sensitivity: 20 μ V/div (starting point)
Recording site: Active:	12 – 14 cm proximal to the cathode in the wrist crease between the flexor carpi radialis (FCR) and palmaris longus tendons (PL)
Reference:	4 cm proximal to the recording electrode
Ground:	Placed between the stimulating and recording electrodes
Stimulation:	(anode is 2.5 cm distal to cathode)
Wrist:	Ring electrode placed on the midportion of the proximal phalanx of the index finger (or middle finger)
Stimulation Parameters:	Sensory NCS Stimulus duration: 0.05ms (50 μ sec) or as necessary Intensity: just enough to acquire maximal amplitude
Measurements:	Distance between active recording electrode and stimulation Latency (msec) and amplitude (μ V) for SNAP
Calculations:	Sensory conduction velocity if required



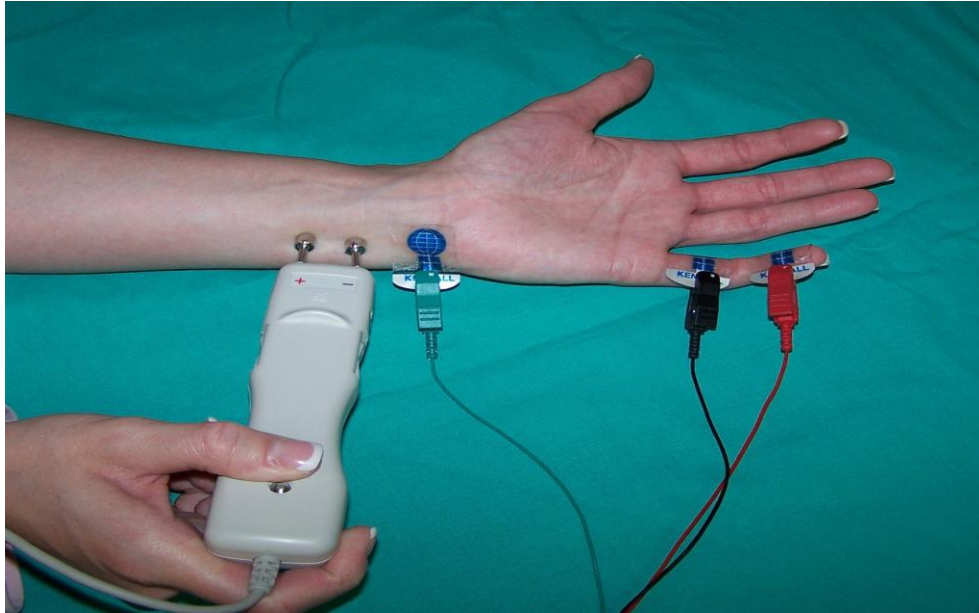
Median Sensory Study, Orthodromic

Carpal Tunnel Syndrome, an Overview

Ulnar Sensory Study, Antidromic

Patient Position:	Supine with arm extended at side
Skin Prep:	Clean with alcohol, temperature check (32 – 34 °C per your lab standards)
Recording Parameters:	Sensory NCS Filters: 20Hz – 3kHz, or as your lab standards dictate Timebase/Sweep Speed: 1 or 2 ms/div Gain/Sensitivity: 20 μ V/div (starting point)
Recording site:	
Active:	Ring electrode placed on midportion of the proximal phalanx of the little finger (digit V)
Reference:	Ring electrode placed on the midportion of the middle phalanx of the little finger (digit V)
Ground:	Placed between the stimulating and recording electrodes
Stimulation:	(anode is 2.5 cm proximal to cathode)
Wrist:	Applied 11 – 13 cm proximal to the active recording electrode
Stimulation Parameters:	Sensory NCS Stimulus duration: 0.05ms (50 μ sec) or as necessary Intensity: just enough to acquire maximal amplitude
Measurements:	Distance between active recording electrode and stimulation Latency (msec) and amplitude (μ V) for SNAP
Calculations:	Sensory conduction velocity if required

Carpal Tunnel Syndrome, an Overview



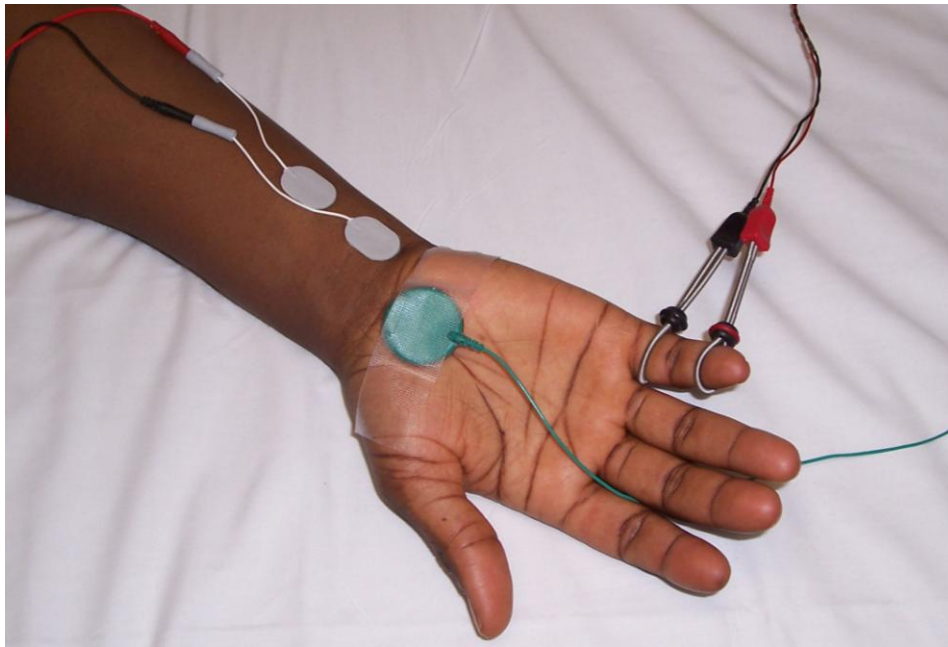
Ulnar Sensory Study, Antidromic

Ulnar Sensory Study, Orthodromic

Patient Position:	Supine with arm extended at side
Skin Prep:	Clean with alcohol, temperature check (32 – 34 °C per your lab standards)
Recording Parameters:	Sensory NCS Filters: 20Hz – 3kHz, or as your lab standards dictate Timebase/Sweep Speed: 1 or 2 ms/div Gain/Sensitivity: 20 μ V/div (starting point)
Recording site:	
Active:	11 – 13 cm proximal to the cathode in the medial portion of the wrist along side the flexor carpi ulnaris tendon
Reference:	4 cm proximal to the recording electrode
Ground:	Placed between the stimulating and recording electrodes

Carpal Tunnel Syndrome, an Overview

Stimulation:	(anode is 2.5 cm distal to cathode)
Wrist:	Ring electrode placed on the midportion of the proximal phalanx of the little finger (digit V)
Stimulation Parameters:	Sensory NCS Stimulus duration: 0.05ms (50 μ sec) or as necessary Intensity: just enough to acquire maximal amplitude
Measurements:	Distance between active recording electrode and stimulation Latency (msec) and amplitude (μ V) for SNAP
Calculations:	Sensory conduction velocity if required



Ulnar Sensory Study, Orthodromic

Comparison studies:

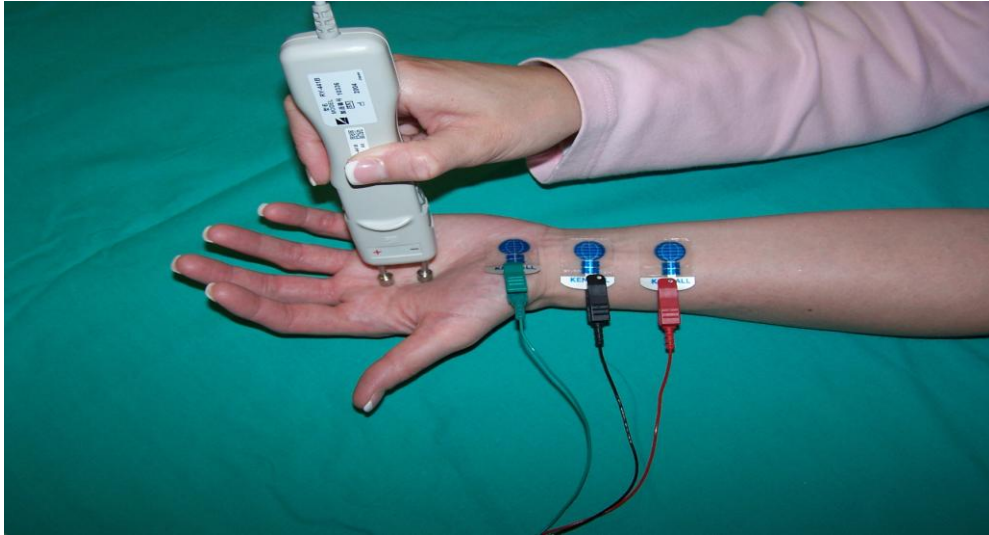Transcarpal Median to Ulnar Palmar Sensory Study

Patient Position: Supine with arm supinated and extended at side

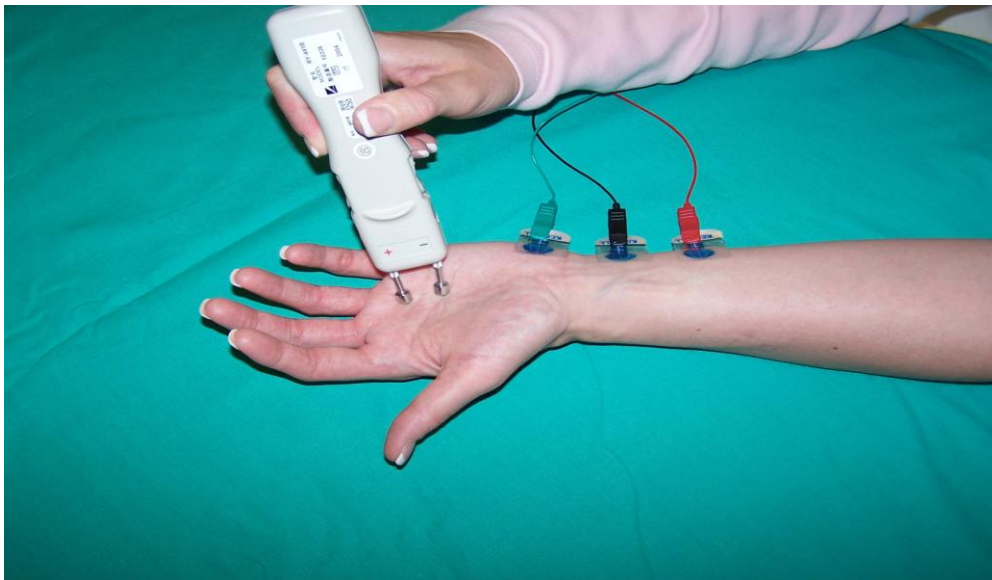
Carpal Tunnel Syndrome, an Overview

Skin Prep:	Clean with alcohol, temperature check (32 – 34 °C per your lab standards)
Recording Parameters:	Sensory NCS
Median –	
Recording site: Active:	Placed 2 cm proximal to the distal wrist crease between the flexor carpi radialis (FCR) and pollicis longus (PL) tendons
Reference:	Placed 4 cm proximal to the active recording electrode along the median nerve
Ground:	Placed between the recording and stimulating electrodes
Stimulation: Cathode/Anode	Applied 8 cm distal to the active recording electrode between the index and third digit Anode is 2.5 cm distal to the cathode
Ulnar –	
Recording site: Active:	Placed 2 cm proximal to the distal wrist crease, just anterior to the flexor carpi ulnaris tendon
Reference:	Placed 4 cm proximal to the active recording electrode along the ulnar nerve
Ground:	Placed between the stimulating and recording electrodes
Stimulation: Cathode/Anode	Applied 8 cm distal to the active recording electrode between the fourth and fifth digit Anode is 2.5 cm distal to the cathode
Stimulation Parameters:	Sensory NCS
Measurements:	Distance between active recording electrode and cathode Latency and amplitude of SNAP
Calculations:	Latency (msec) difference between the two nerves

Carpal Tunnel Syndrome, an Overview



Median



Ulnar

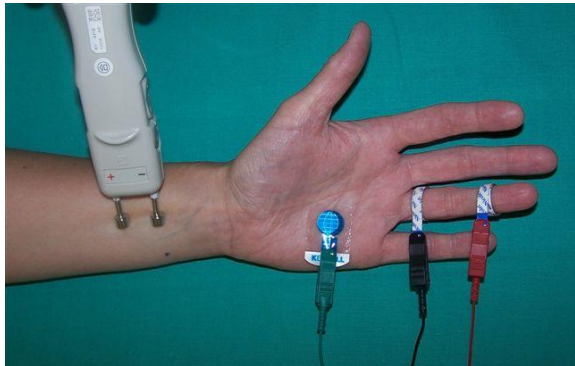
Ring Finger Comparison Study – Antidromic

Patient Position: Supine with arm pronated and extended at side

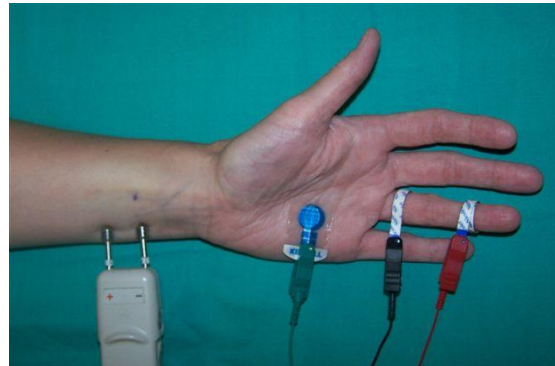
Skin Prep: Clean with alcohol, temperature check (32 – 34 °C per your lab standards)

Carpal Tunnel Syndrome, an Overview

Recording Parameters:	Sensory NCS
Recording site:	
Active:	Ring electrode placed on midportion of the proximal phalanx of the ring finger
Reference:	Ring electrode placed on the midportion of the middle phalanx of the ring finger
Ground:	Placed between the stimulating and recording electrodes
Stimulation:	
Median	Applied 10 cm proximal to the recording electrode in the wrist between the flexor carpi radialis (FCR) and palmaris tendons (PL)
Ulnar	Applied 10 cm proximal to the recording electrode in the wrist anterior to the flexor carpi ulnaris tendon
Stimulation Parameters:	Sensory NCS
Measurements:	Between active recording electrode and cathode Latency (msec) difference between the two sites
Calculations:	None required, although some may calculate the CV from cathode to recording electrode.



Median Stim



Ulnar Stim

Thumb Comparison Study, Antidromic

Patient Position: Supine with arm pronated and extended at side

Skin Prep: Clean with alcohol, temperature check (32 – 34 °C per your lab standards)

Recording Parameters: Sensory NCS

Recording site:
Active: Ring electrode placed on midportion of the proximal phalanx of the thumb

Reference: Ring electrode placed on the midportion of the middle phalanx of the thumb

Ground: Placed between the stimulating and recording electrodes

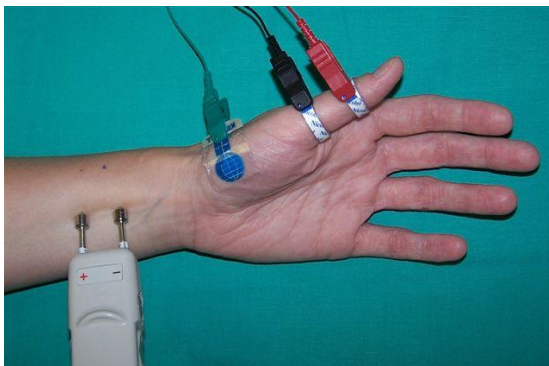
Stimulation:
Median Applied 10 cm proximal to the recording electrode in the wrist between the flexor carpi radialis (FCP) and palmaris tendons (PL)

Radial Applied 10 cm proximal to the recording electrode over the dorsolateral aspect of the radius

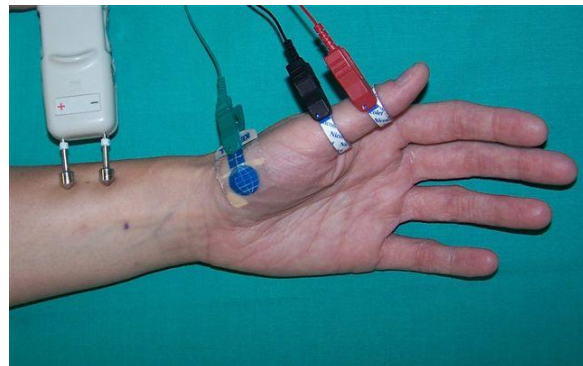
Stimulation Parameters: Sensory NCS

Measurements: Between active recording electrode and wrist
Latency difference (msec) between the two sites

Calculations: None required



Median Stimulation



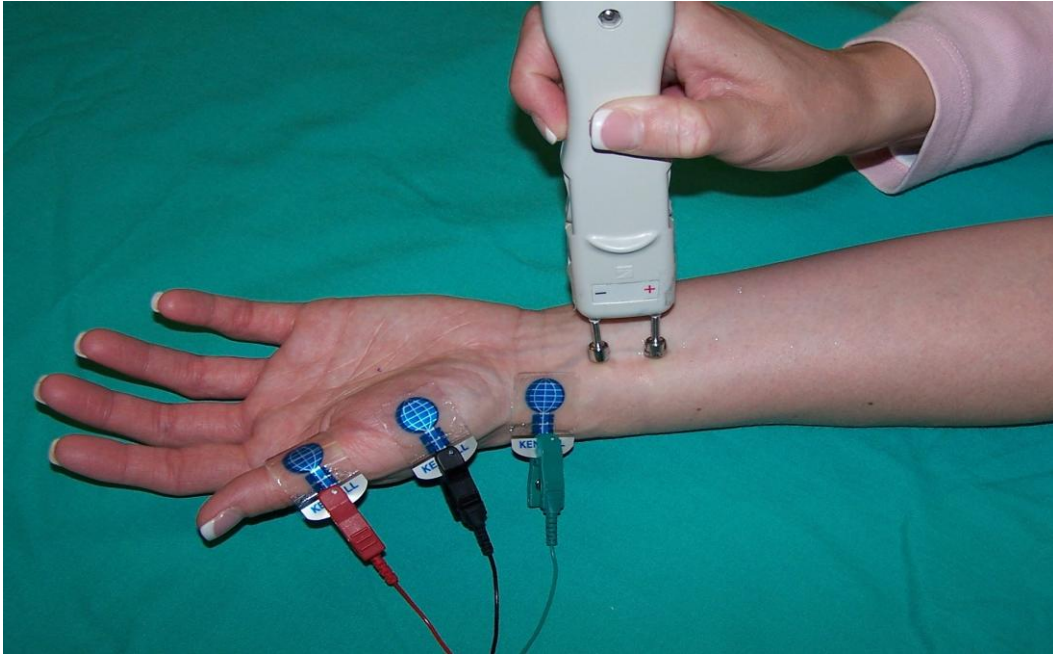
Radial Stimulation

Carpal Tunnel Syndrome, an Overview

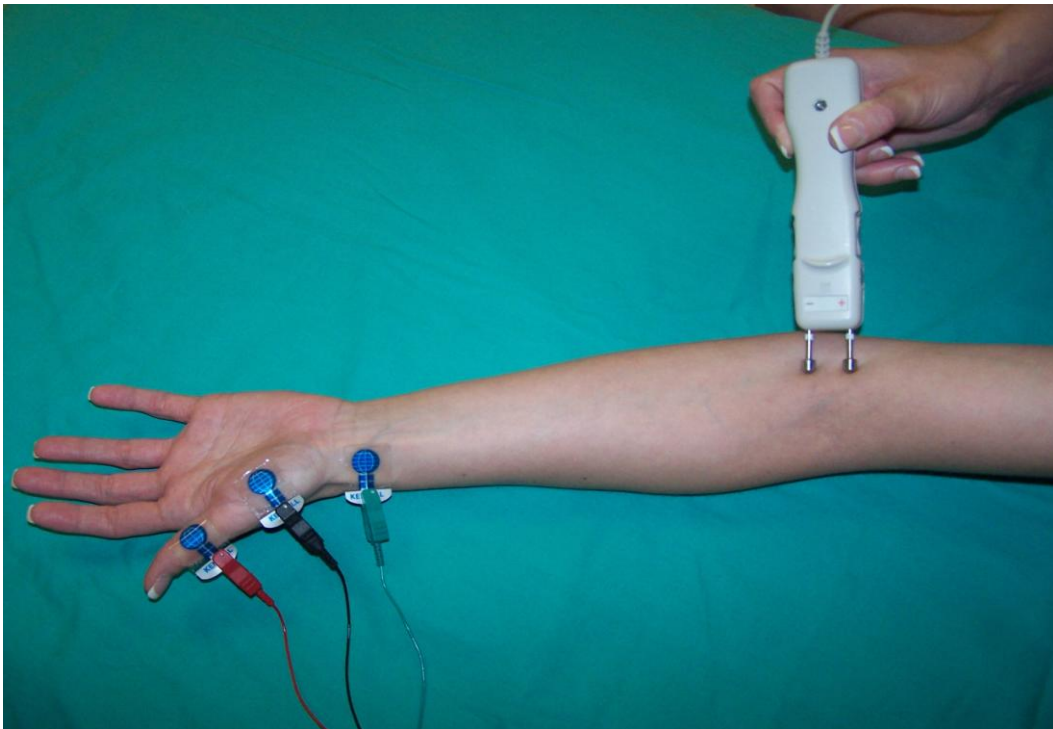
Median Motor Study

Patient Position:	Supine with arm supinated and extended at side
Skin Prep:	Clean with alcohol, temperature check (32 – 34 °C per your lab standards)
Recording Parameters:	Motor NCS Filters: 2Hz – 10kHz, or as your lab standards dictate Timebase/Sweep Speed: 2 or 5 ms/div Gain/Sensitivity: 5 mV/div (starting point)
Recording site: Active:	Placed over the belly of the Abductor Pollicis Brevis (APB), ½ distance between metacarpophalangeal (MCP) joint of thumb and midpoint of the distal wrist crease
Reference:	Placed on the distal phalanx of the thumb
Ground:	Placed between the stimulating and recording electrodes
Stimulation:	(cathode distal)
Wrist:	Applied 2 cm proximal to the distal wrist crease between the flexor carpi radialis (FCR) and the palmaris longus (PL) tendons
Elbow:	Applied at the elbow crease, just medial to biceps tendon
Stimulation Parameters:	Motor NCS Stimulus duration: 0.05ms (50µsec) or as necessary Intensity: enough to acquire supramaximal amplitude
Measurements:	Between active recording electrode and wrist Between wrist and elbow Latency (ms) and amplitude (mV) for CMAP recordings
Calculations:	Conduction velocity wrist to elbow

Carpal Tunnel Syndrome, an Overview



Wrist

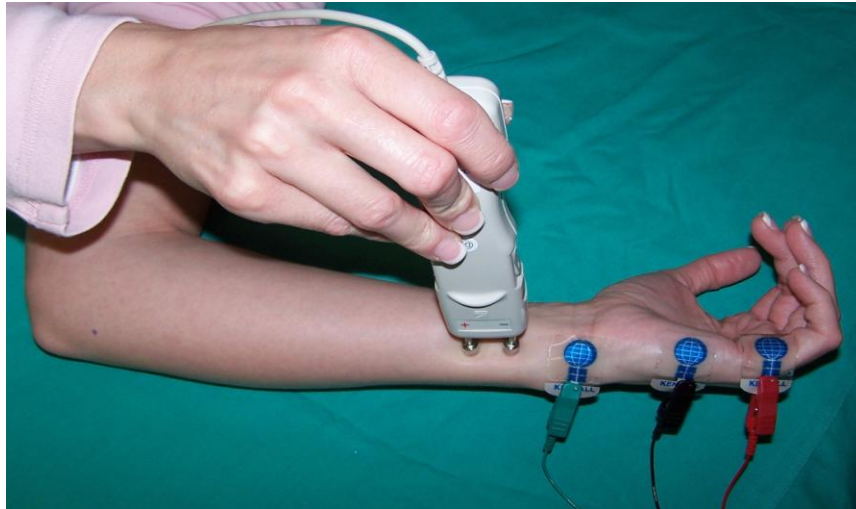


Elbow

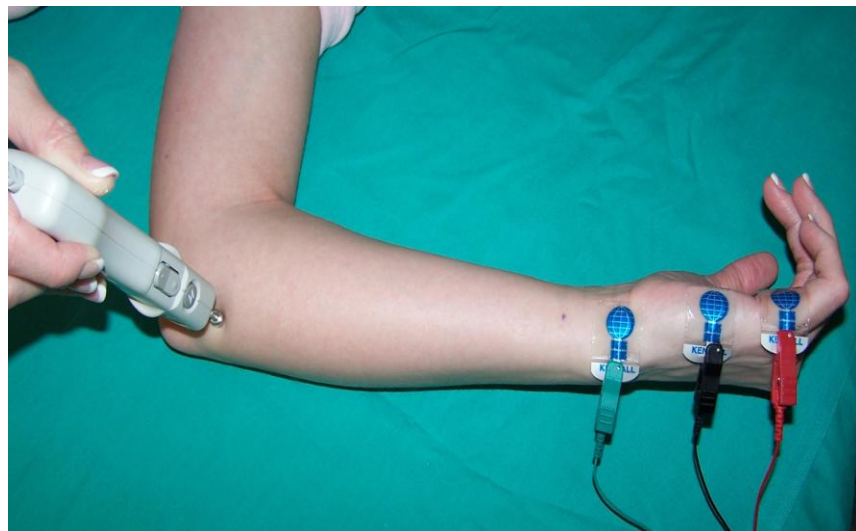
Ulnar Motor Study

Patient Position:	Supine, or on their side with arm supinated and abducted 70-90 degrees
Skin Prep:	Clean with alcohol, temperature check (32 – 34 °C per your lab standards)
Recording Parameters:	Motor NCS Filters: 2Hz – 10kHz, or as your lab standards dictate Timebase/Sweep Speed: 2 or 5 ms/div Gain/Sensitivity: 5 mV/div (starting point)
Recording site: Active:	Placed on the belly of the Abductor Digiti Minimi (ADM) ½ distance between the distal wrist crease and the base of the fifth digit
Reference:	Placed on the proximal phalanx of the fifth digit
Ground:	Placed between the stimulating and recording electrodes
Stimulation:	(cathode distal)
Wrist:	Applied 2 cm proximal to the distal wrist crease, anterior to the flexor carpi ulnaris tendon
Below elbow: (BE)	Applied 2-4 cm distal to the ulnar groove on the medial side of the forearm
Above elbow: (AE)	Applied at least 10 cm proximal to the below elbow site on the medial aspect of the arm
Stimulation Parameters:	Motor NCS Stimulus duration: 0.05ms (50µsec) or as necessary Intensity: enough to acquire supramaximal amplitude
Measurements:	Between the active recording electrode and wrist following a straight line Wrist to BE following contour of the medial aspect of the arm Between BE and AE through the ulnar groove following contour of the medial aspect of the arm Latency (msec) and amplitude (mV) for CMAP recordings
Calculations:	Motor conduction velocity wrist to BE and wrist to AE

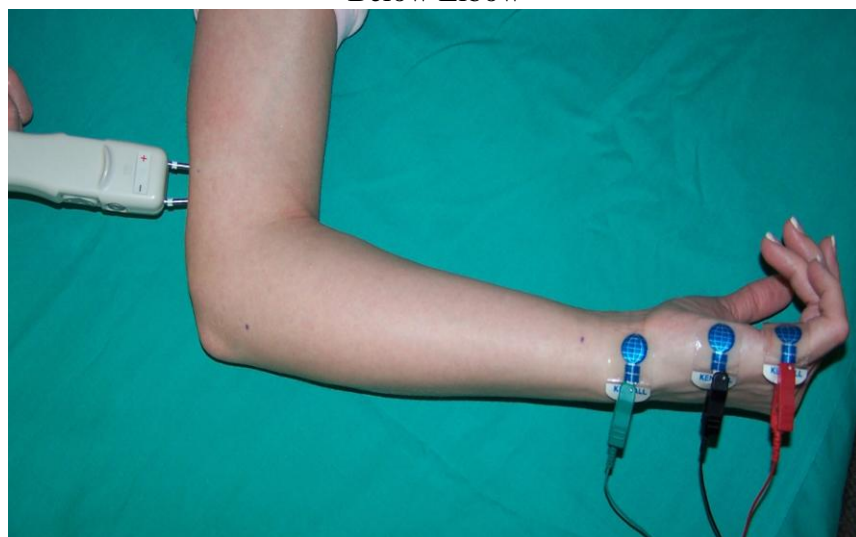
Carpal Tunnel Syndrome, an Overview



Wrist



Below Elbow

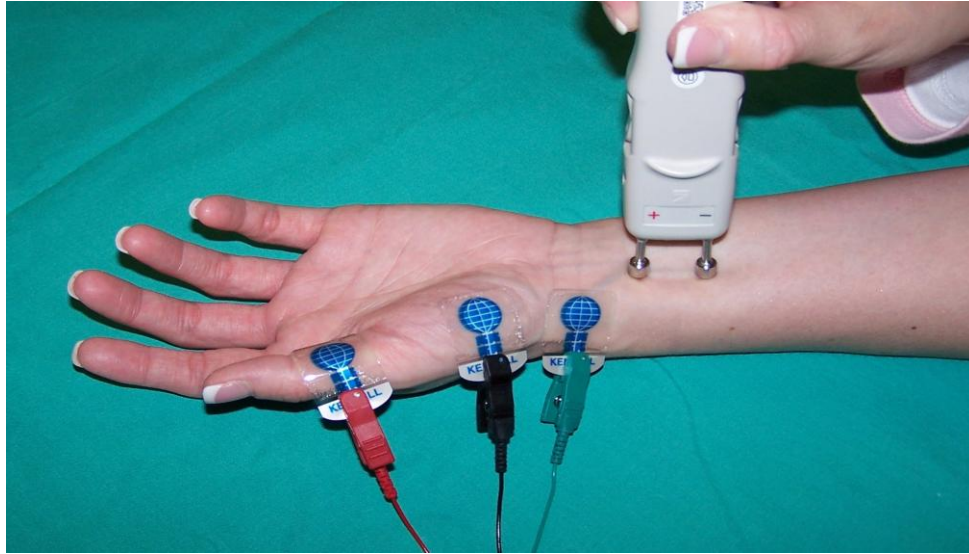


Above Elbow

Carpal Tunnel Syndrome, an Overview

F Wave Study (Median Nerve)

Patient Position:	Supine with arm supinated and extended at side
Skin Prep:	Clean with alcohol, temperature check (32 – 34 °C per your lab standards)
Recording Parameters:	Motor NCS Filters: 2Hz – 10kHz, or as your lab standards dictate Timebase/Sweep Speed: 5 ms/div Gain/Sensitivity: 5 mV/div (starting point) and 500µV in split screen
Recording site: Active:	Placed over the belly of the Abductor Pollicis Brevis (APB) ½ distance between the metacarpophalangeal (MCP) joint of thumb and midpoint of distal wrist crease
Reference:	Placed on the distal phalanx of the thumb
Ground:	Placed between the stimulating and recording electrodes
Stimulation:	(cathode proximal)
Stimulation Parameters:	Motor NCS Stimulus duration: 0.05ms (50µsec) or as necessary Intensity: enough to acquire supramaximal amplitude
Wrist:	Applied 2 cm proximal to the distal wrist crease between the flexor carpi radialis (FCR) and palmaris longus (PL) tendons
Measurements:	Shortest reproducible F wave latency (msec) out of a series of at least 10 responses



F-wave study, Median

Median 2nd Lumbrical to Ulnar 2nd Volar Interosseous Motor Comparison Study (2L2IO)

- Patient Position: Supine with arm supinated and extended at side
- Skin Prep: Clean with alcohol, temperature check (32 – 34 °C per your lab standards)
- Recording Parameters: Motor NCS
Filters: 2Hz – 10kHz, or as your lab standards dictate
Timebase/Sweep Speed: 2 or 5 ms/div
Gain/Sensitivity: 5 mV/div (starting point)
- Recording site: (the same for both median and ulnar)
Active: Placed between the 2nd and 3rd metacarpal bones in the palm of the hand
- Reference: Distally over the proximal interphalange joint (PIP) of the 2nd or 3rd digit
- Ground: Placed between the recording and stimulating electrodes or on the dorsum of the hand

Carpal Tunnel Syndrome, an Overview

Stimulation:

Median –

Cathode/Anode: Applied 10 cm distal to the active recording electrode in the middle of the wrist between the flexor carpi radialis tendon and the palmaris longus tendon.

Ulnar –

Cathode/Anode: Applied 10 cm distal to the active recording electrode in the medial portion of the wrist along side the flexor carpi ulnaris tendon

Stimulation

Motor NCS

Parameters:

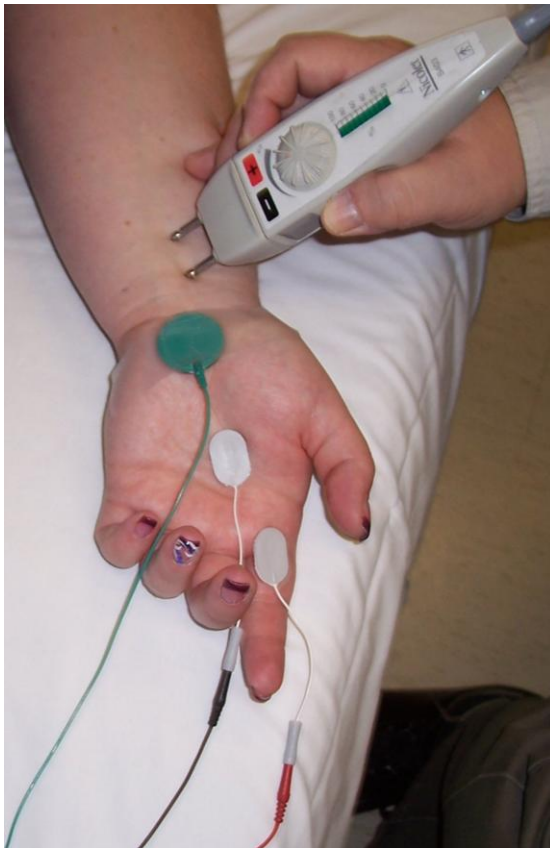Stimulus duration: 0.05ms (50 μ sec) or as necessary
Intensity: enough to acquire supramaximal amplitude

Measurements:

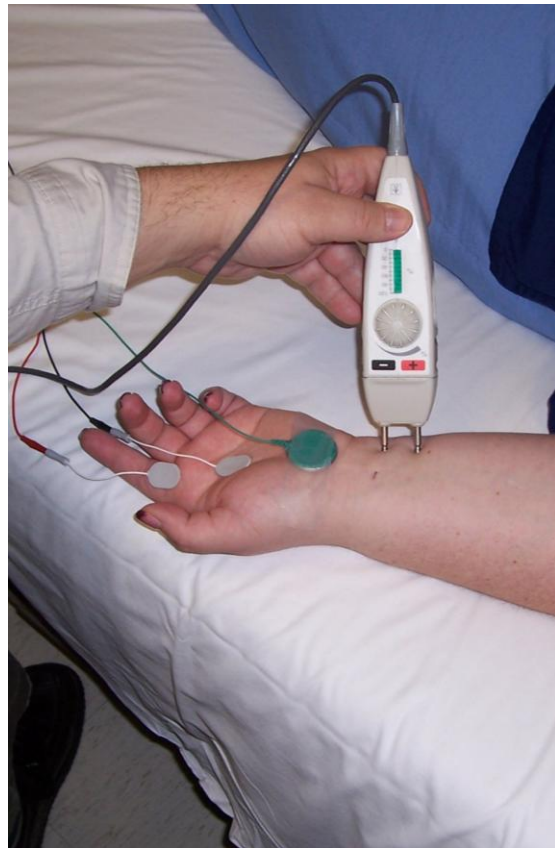Latency and amplitude of CMAP

Calculations:

Latency difference between the two nerves



Median Stim



Ulnar Stim

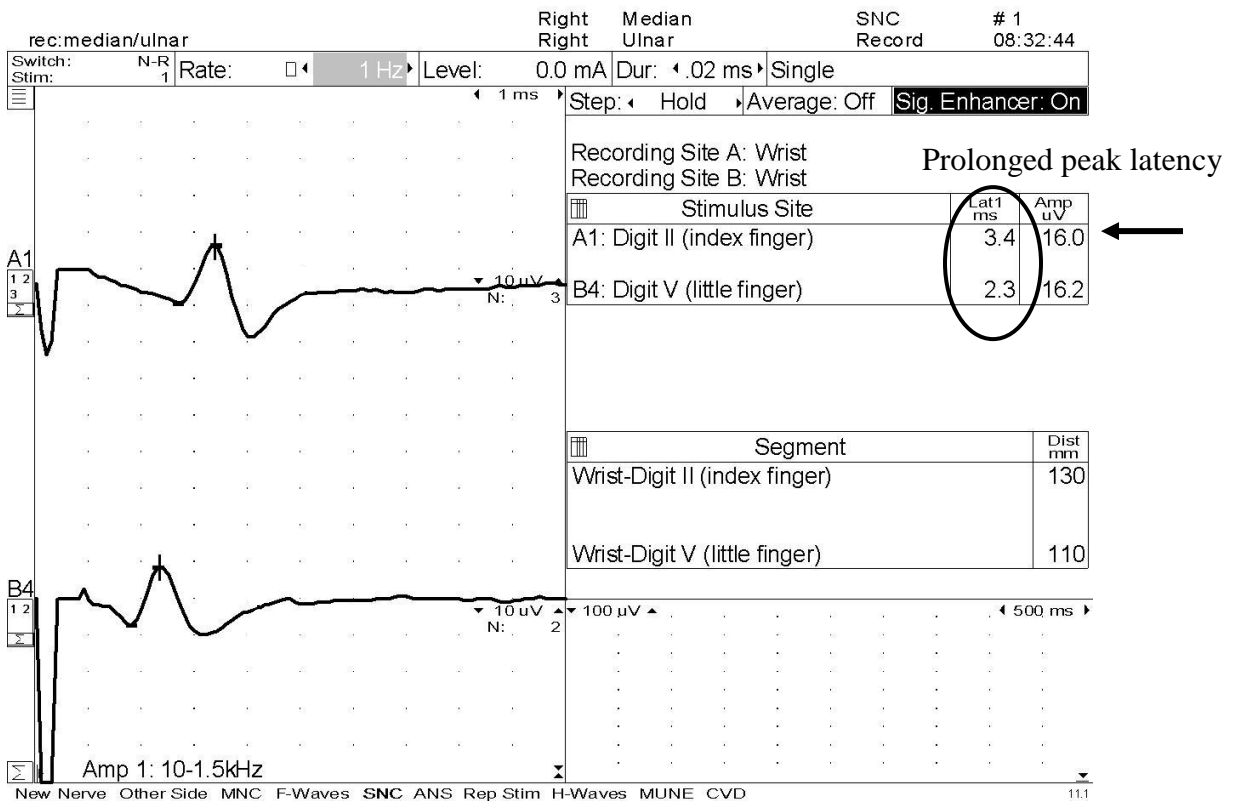
Carpal Tunnel Syndrome, an Overview

Case Studies:

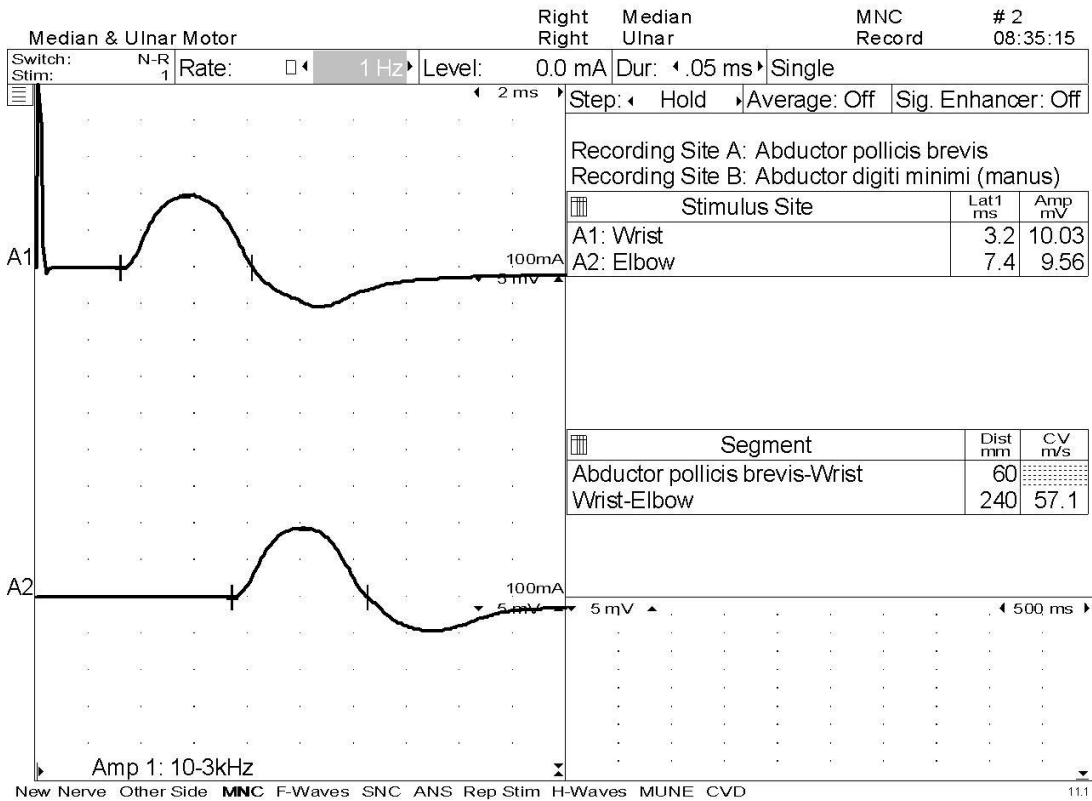
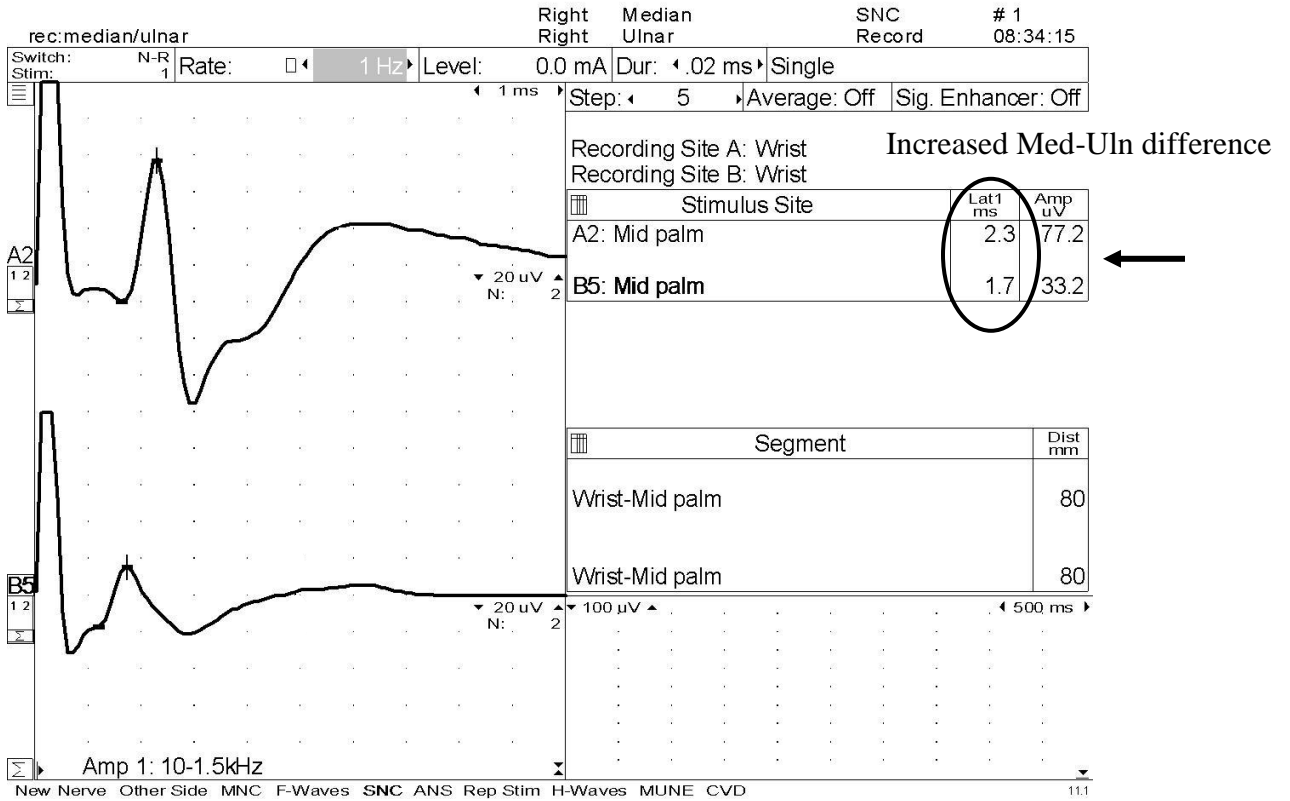
Case 1 – For your convenience values outside the normal range are noted. Normal values for this age are stated below the waveforms.

History: This is a 42 year-old right-handed patient with a several month history of hand pain and numbness in her right hand. The paresthesias are worse at night and wake her up several times a night. There is no history of diabetes. She works as a store clerk.

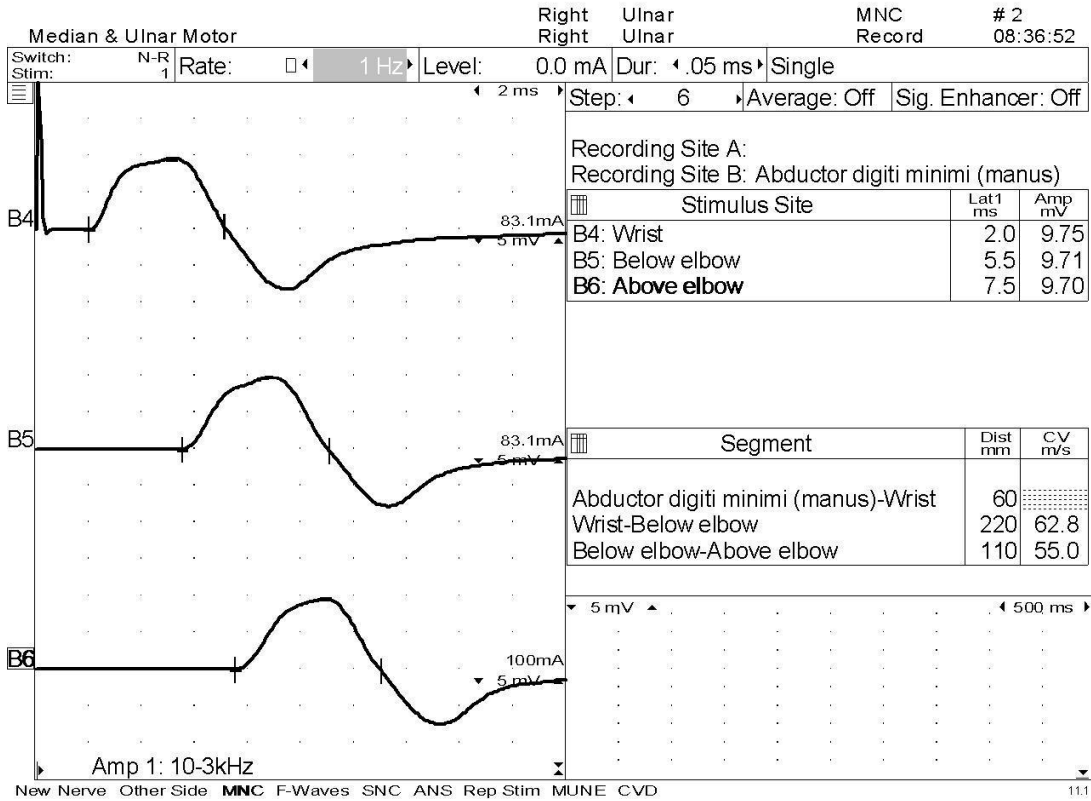
Temperature: Right hand, 33.5°C



Carpal Tunnel Syndrome, an Overview



Carpal Tunnel Syndrome, an Overview



Normal values:

Median MNC DML: ≤ 4.2 , Amp: ≥ 4 , CV ≥ 49
 Ulnar MNC DML: ≤ 3.8 , Amp: ≥ 6 , CV ≥ 49 ,
 CV across elbow may slow ≤ 10

Median SNC Peak Lat: ≤ 3.2 , Amp: ≥ 12
 Ulnar SNC Peak Lat: ≤ 2.8 , Amp: ≥ 10
 Palmar diff ≤ 0.4

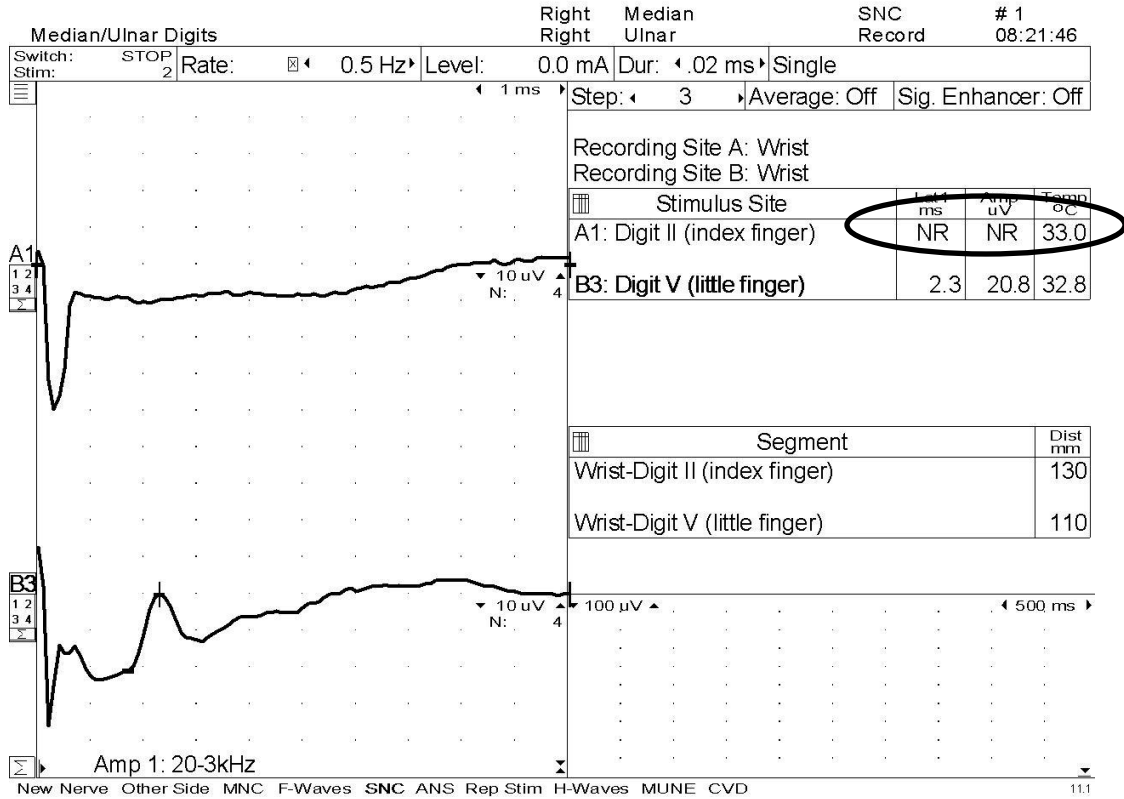
Mild carpal tunnel syndrome as noted with prolonged sensory latency and normal motor latencies. In this case F-waves and Needle EMG would probably have been of very little use. Every physician is different, but we would have tried to downplay these findings to steer the referring physician to conservative treatment instead of surgery.

Carpal Tunnel Syndrome, an Overview

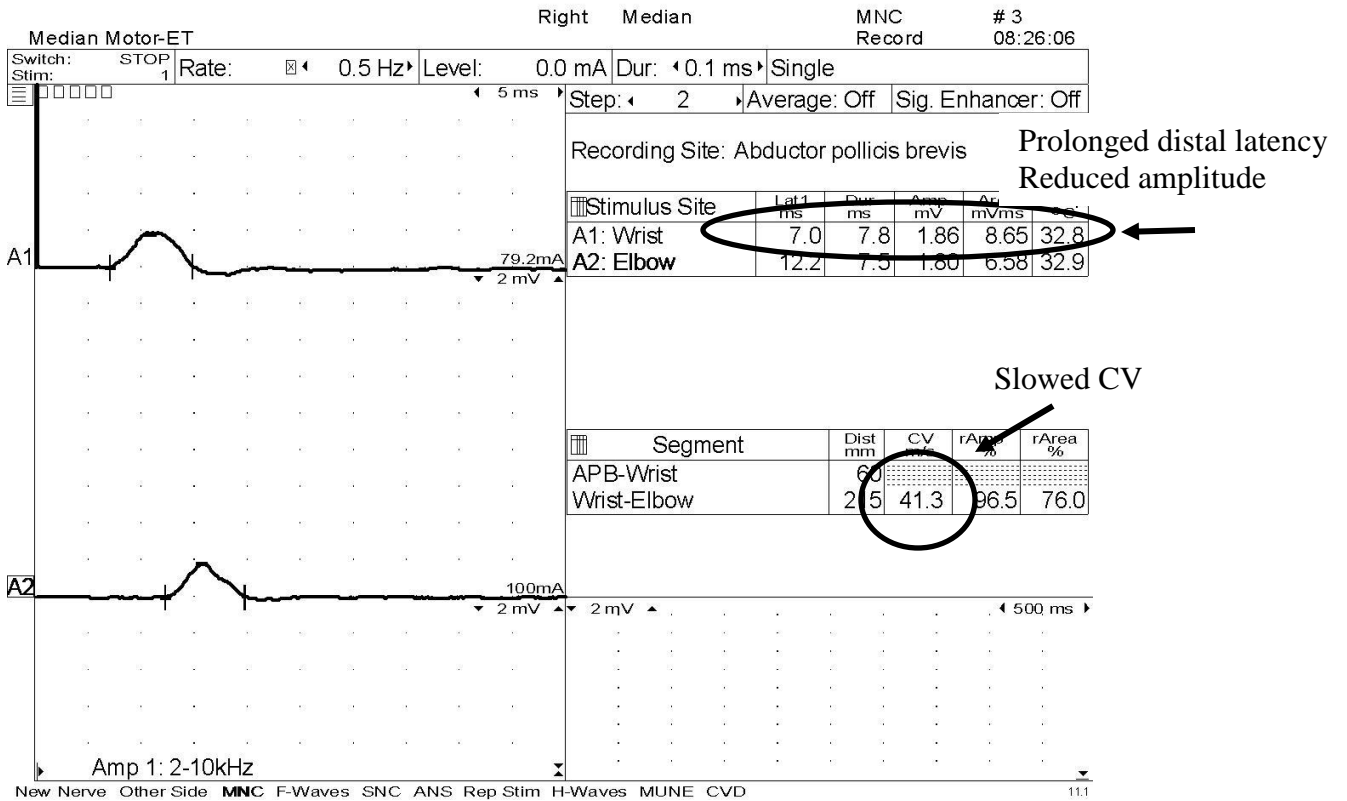
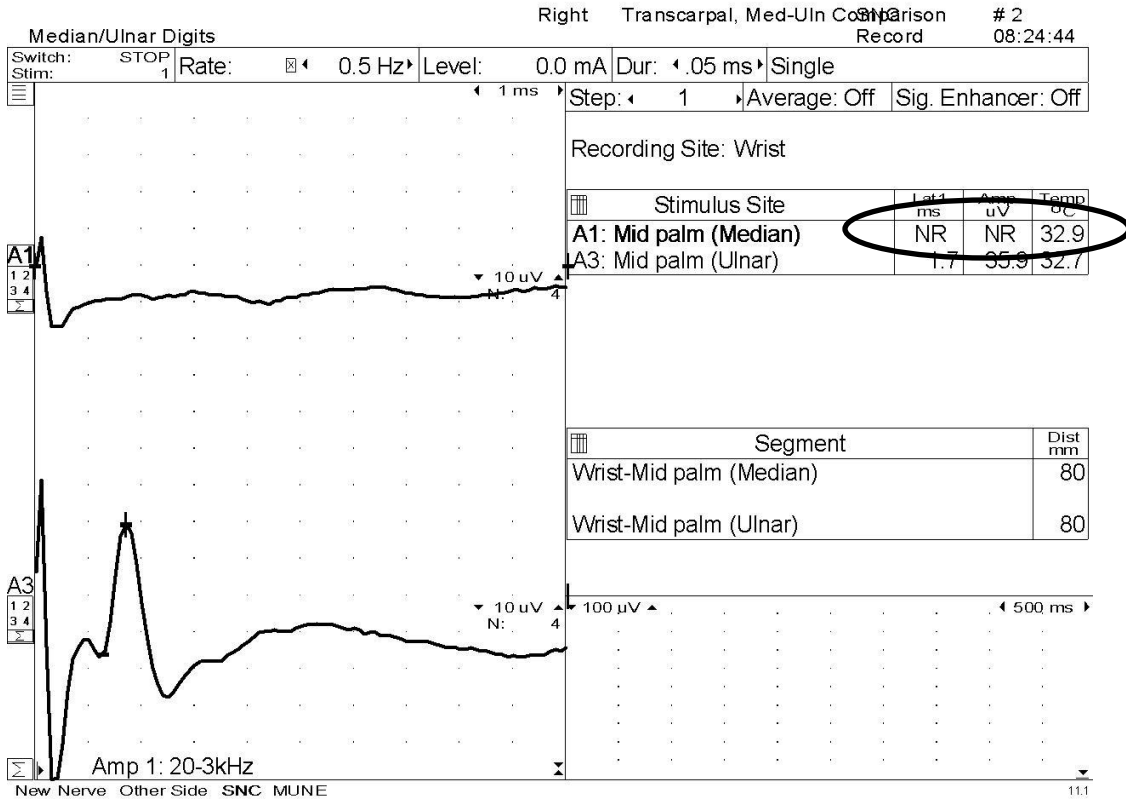
Case 2 – For your convenience values outside the normal range are noted. Normal values for this age are stated below the waveforms.

This is a 64 year-old farmer with a several year history of hand numbness and weakness; right more than left. On examination there is obvious atrophy of the thenar muscles on the right.

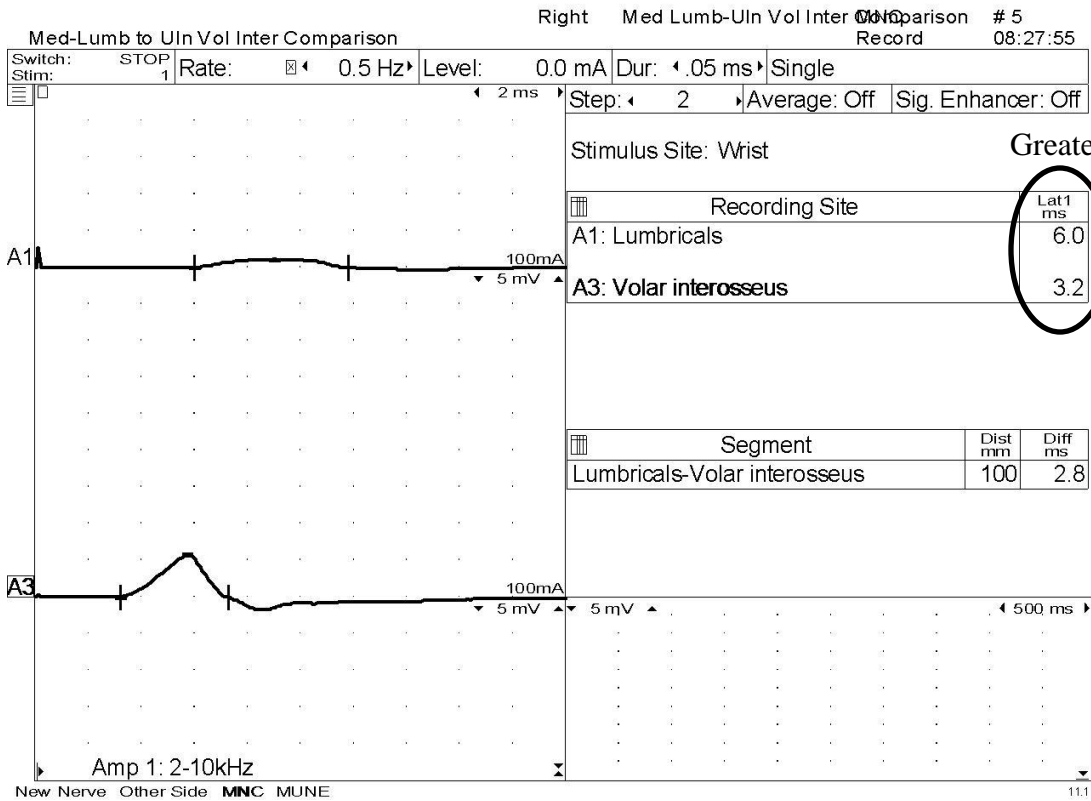
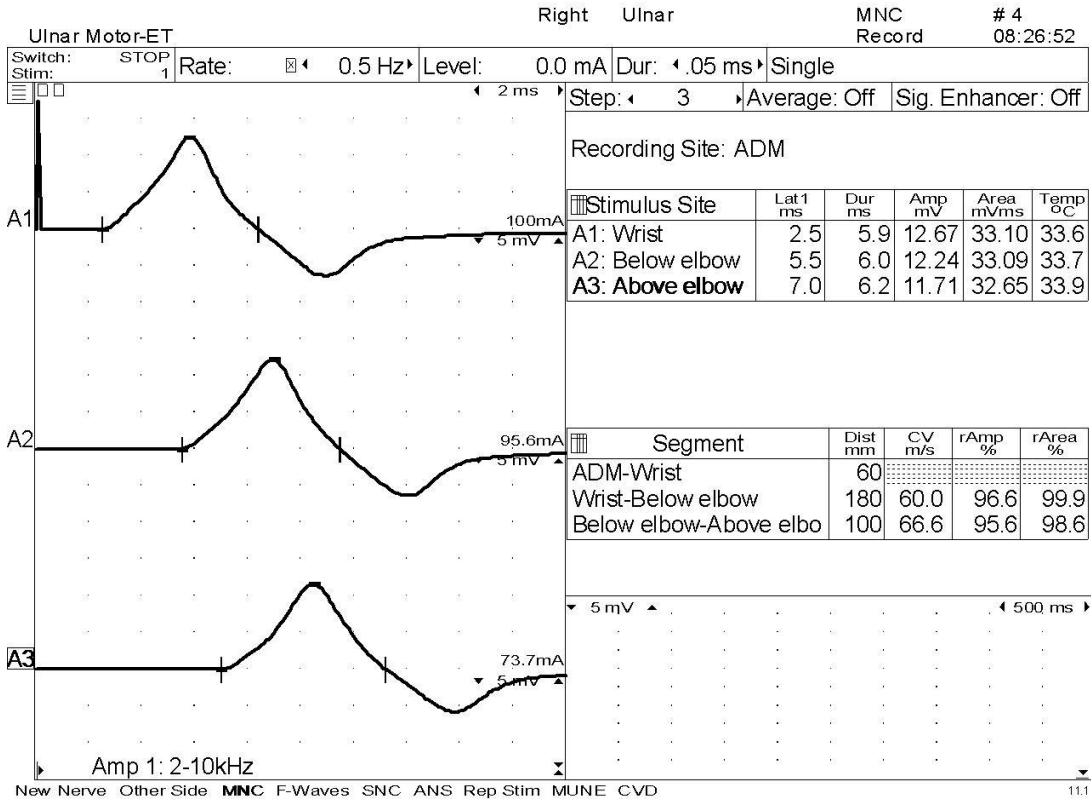
Temperatures: Right arm: 33.0 °C



Carpal Tunnel Syndrome, an Overview



Carpal Tunnel Syndrome, an Overview



Carpal Tunnel Syndrome, an Overview

Normal values:

Median MNC	DML: ≤ 4.2 , Amp: ≥ 4 , CV ≥ 49	Median SNC	Peak Lat: ≤ 3.2 , Amp: ≥ 12
Ulnar MNC	DML: ≤ 3.8 , Amp: ≥ 6 , CV ≥ 49 , CV across elbow may slow ≤ 10	Ulnar SNC	Peak Lat: ≤ 2.8 , Amp: ≥ 10
	Median 2 nd IO to Ulnar 2 nd VI difference ≤ 1.2	Palmar diff	≤ 0.4

This is an example of a moderate carpal tunnel syndrome. If the needle EMG to the abductor pollicis brevis were abnormal this would move this to severe. The distal motor latency of the median motor to the APB was greater than 1.8 msec longer than the ulnar distal motor latency which would make the median to second lumbrical to ulnar second volar interosseous (2L2IO) unnecessary. In this case, the reason we did perform the 2L2IO because the slowed forearm conduction velocity.

Bibliography

Blum Andrew S. and Seward B. Rutkove, eds. The Clinical Neurophysiology Primer. Humana Press Inc. Totowa, New Jersey. 2007.

Buschbacher, Ralph M. and Hathan D. Prahlow. Manual of Nerve Conduction Studies, 2nd Ed. Demos Medical Publishing, New York. 2006.

Daube, Jasper, ed. Clinical Neurophysiology. F.A. Davis Company, Philadelphia. 1996.

Dawson, David M., Marl Hallett and Lewis H. Millender. Entrapment Neuropathies. Little, Brown and Company, Boston. 1983

Dumitru, Daniel, Anthony Amato and Machiel Zwarts. Electrodiagnostic Medicine, 2nd Ed. Hanley and Belfus, Philadelphia. 2002.

Jablecki, Charles K., MD, et al. eds. "Practice Parameter and Literature Review of the Usefulness of Nerve Conduction Studies and Needle Electromyography for the Evaluation of Patients with Carpal Tunnel Syndrome." Muscle and Nerve 25 (2002): 918-922

Kimura, Jun. Electrodiagnosis in Diseases of the Nerve and Muscle, Principles and Practice. 3rd Ed. Oxford, New York, Philadelphia. 2001.

Oh, Shin. Clinical Electromyography: Nerve Conduction Studies. 2nd Ed. Williams and Wilkins, Baltimore. 1993.

Perotto, Aldo. Anatomical Guide for the Electromyographer: the Limbs and Trunk. 4th Ed. Charles C. Thomas, Springfield, IL. 2005.

Preston, David and Barbara Shapiro. Electromyography and Neuromuscular Disorders: Clinical-Electrophysiologic Correlations. 2nd Ed. Elsevier, Philadelphia. 2005.